Urine Sediment

Urine sediment analysis is part of the routine urinalysis and its purpose is to detect, to identify and to quantify formed elements (particles) present in the urine. Sediment analysis is often performed if abnormal findings are seen in the physical and chemical examination or if indicated by the patient´s condition (clinical history). It is important in the initial diagnosis of renal disease as well as in monitoring of renal disease progression, the detection of urinary tract infection and other systemic diseases.

Particles examined are cells (white blood cells, red blood cells, and epithelial cells), casts, pathogens (e.g. bacteria, yeast, and parasites), crystals and others (e.g. mucus, sperm). These particles can originate from throughout the urinary tract (from the kidneys to the urethra) but can also result from a contamination (e.g. menstrual blood).

Most commonly, urinary sediment analysis is performed manually by microscopic examination with the objectives 10x and 40x of either a centrifuged (concentrated) or non-centrifuged (native) urine sample. The judgment if a result is normal or pathological is referred to reference values, which are depending on the sediment preparation protocol as well as the sediment examination process, both varying among laboratories. To increase standardization of this time-consuming and labor-intensive method, automated solutions are available.

The Urilyzer® Sed from Analyticon offers a standardized and automated microscopy. Whole viewfield images of native samples are taken under the objectives 10x and 40x (similar to manual microscopy) and particles are classified into 11 categories. These images are archived, allowing full traceability, and are presented to the user for review who may perform sub-classification if desired. Sorting out negative samples, which are automatically verified, allows the user to focus on those with pathological findings resulting in an improved workflow in the urinalysis laboratory.

LP = low power (100 x magnification)
HP = high power (400 x magnification)
Urin. correl. = Urinalysis correlation

→ = Example of the respective particle

All pictures at this poster are made with the Urilyzer® Sed and show a limited selection of possible sediment particles.

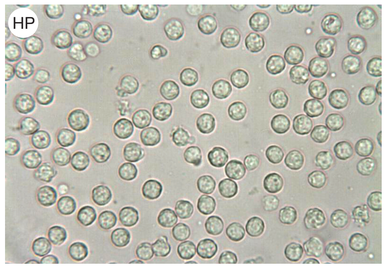

White blood cells (WBCs) – Granulocytes
Appearance: 7 – 14 µm; round to oval shape with a granulated cytoplasm and a segmented nucleus; can occur in clumps
Look-alikes: Crenated RBCs, renal tubular epithelial cells
Urin. correl.: Urine odor and turbidity; Leukocyte esterase (test strip) pos. (non-granular WBCs, e.g. Lymphocytes, will give a negative result); nitrite (test strip) pos. (if nitrite forming bacteria present)

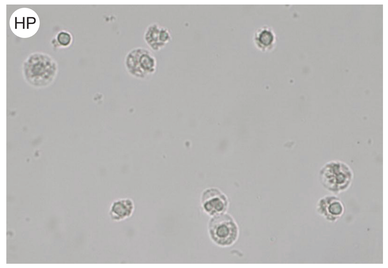

Aging white blood cells (WBCs)
Appearance: Up to 20 – 30 µm; swell to spherical balls (start of lysis); formation of blebs/vacuoles that can detach and become free floating; fused nucleus (sometimes blurred); more granular cytoplasm
Look-alikes: Renal tubular epithelial cells (small round epithelial cells) which are very rare in the urine
Urin. correl.: (See WBCs)

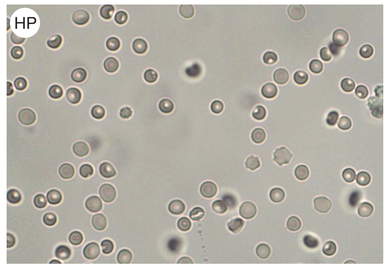

Red blood cells (RBCs) – eumorphic
Appearance: 5 – 8 µm (smaller than WBCs); non-nucleated mostly bi-concave disks without granules; crenated in concentrated urine; ghost cells in dilute urine
Look-alikes: Yeast, round calcium oxalate crystals (monohydrates), air bubbles, oil droplets
Urin. correl.: Urine color (colorless to reddish); blood (test strip) pos.

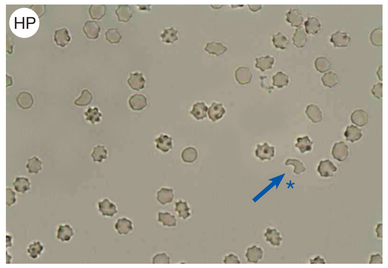

Red blood cells (RBCs) – dysmorphic
Appearance: 5 – 8 µm (sometimes smaller); dysmorphic or fragmented (due to passage through damaged glomerular membrane); without granules and no nucleus
Look-alikes: Yeast
Urin. correl.: Urine color (max. slightly colored); blood (test strip) pos.

* Only dysmorphic RBC in the sample

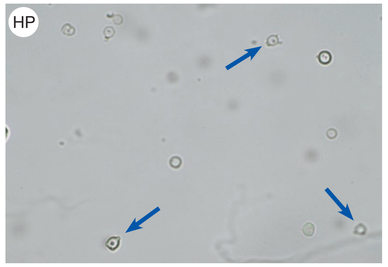

Acanthocytes – type of dysmorphic RBCs
Appearance: 5 – 8 µm (can vary); at least one spherical protuberance (varying surface distribution); without granules and no nucleus
Look-alikes: Yeast
Urin. correl.: Urine color (max. slightly colored); blood (test strip) pos.

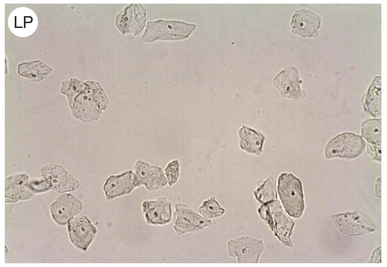

Squamous epithelial cells
Appearance: 30 – 60 µm (largest cells in urine sediment); thin, flat cells with prominent nucleus and fine granulation in cytoplasm
Look-alikes: Non-squamous epithelial cells, nucleus can be misinterpreted as RBC or WBC, folded cells may be misinterpreted as casts
Urin. correl.: Urine turbidity

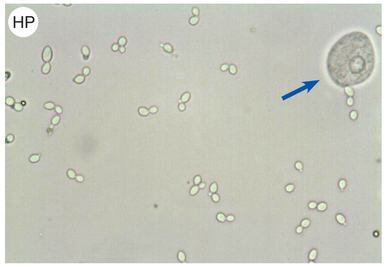

Transitional epithelial cells (Other non-SQ EC or Small round EC depending on origin)
Appearance: 20 – 40 µm; size and shape vary depending on origin (round, polygonal or elongated) with centrally located nucleus and fine granulation in cytoplasm
Look-alikes: Renal tubular epithelial cells, old WBCs
Urin. correl.: Urine turbidity; blood (test strip and sediment) pos. (if malignancy-associated)

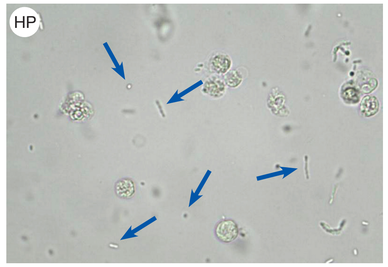

Bacteria
Appearance: < 3 – 10 µm; rod shape or coccoid; single organisms, in chains or in groups
Look-alikes: Amorphous crystals (phosphates and urates)
Urin. correl.: Urine odor and turbidity; Leukocyte esterase (test strip) and WBCs in sediment pos./neg.; nitrite (test strip) pos. (if nitrite forming bacteria present)

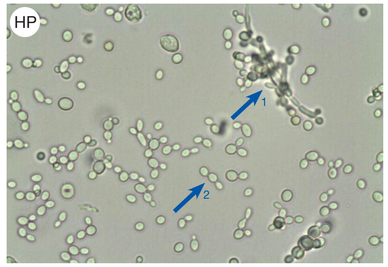

Yeast
Appearance: 5 – 7 µm up to 50 µm (pseudohyphae)[1]; round to oval with thick walls; characteristic budding forms[2] may be present as well as pseudohyphae
Look-alikes: RBCs, acanthocytes, calcium oxalate crystals (monohydrates)
Urin. correl.: Urine turbidity; Leukocyte esterase (test strip) and WBCs in sediment pos./neg.; blood (test strip) pos./neg.

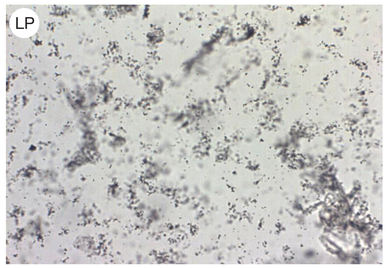

Amorphous crystals – common finding
Appearance: ~ 3 µm; small amorphous and grainy-structure; colorless to light yellow
Look-alikes: Bacteria (cocci)
Urin. correl.: Acidic pH and orange to pink precipitate (urates); neutral to alkaline pH and white to beige precipitate (phosphates)

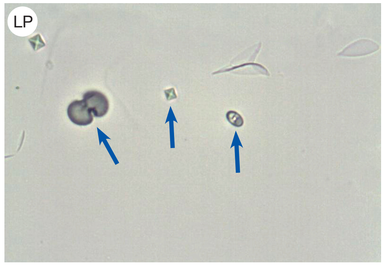

Calcium oxalate crystals – common finding
Appearance: Variable in size; round to oval or spindle (monohydrate); octahedral/pyramid or envelope form (dihydrate); colorless
Look-alikes: Round calcium oxalates can look like RBCs
Urin. correl.: Acidic to neutral (alkaline) pH

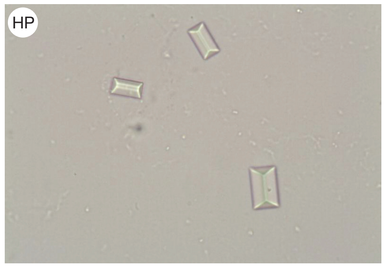

Triple phosphate crystals – common finding
Appearance: Variable size; prism with three to six sides ("coffin lids"); colorless
Look-alikes: Hippuric acid crystals
Urin. correl.: Neutral to alkaline pH

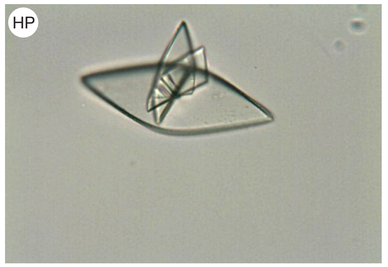

Uric acid crystals – common finding
Appearance: Variable size; mostly rhombic or diamond shape, can also appear as cubes, prisms, lemons, barrels or bands; may cluster together to form stars/rosettes; colorless to yellow to golden brown
Look-alikes: None
Urin. correl.: Acidic pH

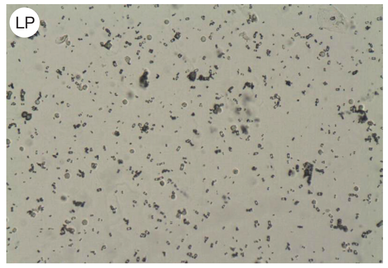

Acid urate crystals – common finding
Appearance: Small; balls; yellow to brown
Look-alikes: None
Urin. correl.: Acidic to neutral pH; old urine sample

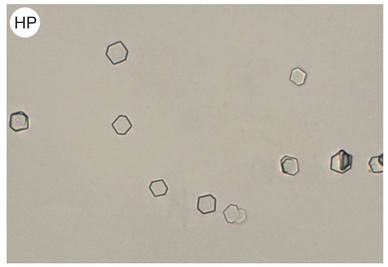

Cystine crystals – rare finding
Appearance: Small to medium size; flat hexagonal plates; often layered; colorless
Look-alikes: None
Urin. correl.: Acidic to neutral pH

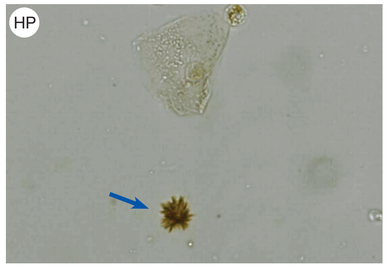

Bilirubin crystals – rare finding
Appearance: Small; fine needles or grainy structures that form clusters; yellow to brown, highly pigmented
Look-alikes: Tyrosine crystals
Urin. correl.: Acidic pH

Hyaline casts – non-pathological casts
Appearance: 100 – 200 µm long and 30 – 50 µm wide; colorless homogenous matrix with cylindrical or cigar shape and parallel sides; matrix often includes fine granulation
Look-alikes: Mucus, Granular casts
Urin. correl.: Urine color and/or blood (test strip and sediment) pos./neg. (strenuous exercise); protein pos.

Red blood cell casts – pathological casts
Appearance: Variable length (> 50 µm); cylindrical or cigar shape and parallel sides with intact RBCs within matrix
Look-alikes: RBC clumps, fatty casts, other cellular casts (e.g. WBC casts) or fungal casts
Urin. correl.: Urine color and/or blood (test strip and sediment) pos.; protein pos.

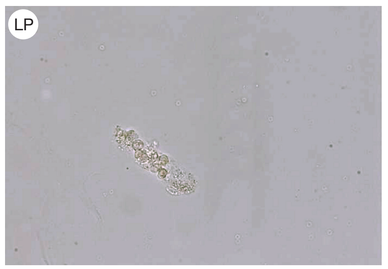

Mixed cell casts – pathological casts
Appearance: Variable length (> 50 µm); cylindrical or cigar shape and parallel sides with intact WBCs and renal epithelial cells within matrix
Look-alikes: WBC clumps, WBC casts, renal epithelial cell casts, fatty casts, granular casts, RBC casts
Urin. correl.: Leukocyte esterase (test strip) and WBCs in sediment pos.; protein pos.; blood (test strip and sediment) pos./neg.; nitrite (test strip) pos./neg.

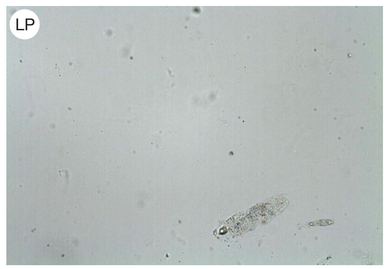

Granular casts – pathological casts
Appearance: Variable length (> 50 µm); cylindrical or cigar shape and parallel sides with small, fine to large, coarse granules within matrix
Look-alikes: Crystal casts, fatty casts, hemoglobin casts, degenerating cellular casts, clumps of small crystals
Urin. correl.: Protein pos.; cellular casts in sediment; blood (test strip and sediment) pos./neg.; Leukocyte esterase and WBCs in sediment pos./neg.

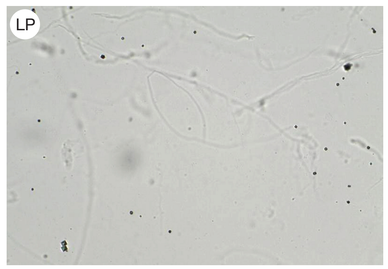

Mucus
Appearance: Variable size/length; delicate, single or clumped threads; ribbon-like strands
Look-alikes: Hyaline casts
Urin. correl.: None

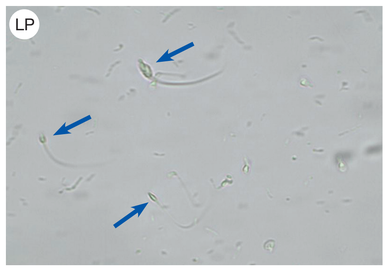

Sperm
Appearance: 3 – 6 µm (head); 40 to 60 µm (tail); round to oval head with a thin, threadlike tail
Look-alikes: RBCs or Yeast, if tail is not perceived
Urin. correl.: None

SP_GB_27_001_01.01_2018-03